



International Journal of Dermatology, Venereology and Leprosy Sciences

E-ISSN: 2664-942X

P-ISSN: 2664-9411

www.dermatologypaper.com

Derma 2023; 6(1): 122-125

Received: 18-04-2023

Accepted: 26-05-2023

Safia Ali Yousef

Dermatology and Venereology
Department, Faculty of
Medicine, Tanta University,
Tanta, Egypt

Yasmina Ahmed El-Attar

Dermatology and Venereology
Department, Faculty of
Medicine, Tanta University,
Tanta, Egypt

Dina Magdy El-Guindy

Department of Pathology,
Faculty of Medicine, Tanta
University, Tanta, Egypt

Noha Nabil

Dermatology and Venereology
Department, Faculty of
Medicine, Tanta University,
Tanta, Egypt

Corresponding Author:

Safia Ali Yousef

Dermatology and Venereology
Department, Faculty of
Medicine, Tanta University,
Tanta, Egypt

Mechanisms and causes of scalp scaling

Safia Ali Yousef, Yasmina Ahmed El-Attar, Dina Magdy El-Guindy and Noha Nabil

DOI: <https://doi.org/10.33545/26649411.2023.v6.i1b.142>

Abstract

Scalp scaling is a frequent and persistent issue that causes a lot of pain, discomfort, and social stigma. Scaling or flaking of the scalp simply denotes a higher rate of epidermal cell turnover. The scalp may be affected locally or diffusely. Although it is frequently asymptomatic, more severe cases may result in pruritus.

Scaling may develop as a result of dry scalp and the vulnerability of the skin's outermost layer, variation in sebaceous gland secretion as in seborrheic dermatitis, immune mediated in which activated T cells penetrate the dermis and trigger cytokines, increasing the development of keratinocytes as in psoriasis, and may be associated with alopecia, a common condition in youngsters and frequently connected to tinea capitis.

Another indicator of atopic dermatitis is scaling on the scalp. Scaling of the scalp may be present in around half of all children with atopic dermatitis, according to studies of infants 0 to 6 months old and kids from birth to 12 years old. Many medical experts are unaware that scalp scaling is a sign of atopic dermatitis, despite the topic being rarely covered in texts.

Keywords: Scalp scaling, seborrheic dermatitis, tinea capitis

Introduction

Scalp scaling is a common issue that causes a lot of pain, discomfort, and social shame whether it is irritated or not. The location, colour, and intensity of the scaling aid in differentiating between normal and pathological diseases. Scaling or flaking on the scalp simply denotes an increase in epidermal cell turnover. There may be isolated or widespread symptoms on the scalp. Even while it frequently goes unnoticed, it might induce pruritus when it is more severe [1, 2].

Characters of scalp scaling

Scales of the scalp may be loose or adherent, large or small, yellow, white or gray, oily or dry, patchy, diffuse or perifollicular, it may be associated with erythema and pruritus or not [3, 4].

Etiological factors of scaling

Scale scaling may be the single or the most distinguishing feature of a range of clinical entities that are pretty well-defined, just like with (SD), psoriasis, and pityriasis amiantacea. Other inflammatory dermatoses that might cause it include atopic dermatitis, discoid lupus erythematosus, lichen planus, and tinea capitis [1]. Dermatomyositis, scabies, and Langerhans cell histiocytosis patients may exhibit it. Less common causes of scalp scaling include pityriasis rubra pilaris, pemphigus foliaceus, and leukaemia cutis [5].

Importance of healthy stratum corneum

Bacteria, toxic chemicals, oxidants, and UV radiation are all prevented from penetrating the stratum corneum by a robust stratum corneum. Sebaceous glands, sweat glands, and decomposing keratinocytes all create oil, which fills the crevices between the corneocytes. The epidermal permeability barrier (EPB), a highly impermeable outer layer, is present to stop water loss. Because of the acids created during the keratinization process, it is also quite acidic [6, 7].

By preserving the SC's water content, pH, and flexibility, the filaggrin protein in the lower

SC releases a variety of free amino acids, salts, and hydroscopic chemicals over the upper SC, acting as natural moisturising agents. The demand for humectancy given by natural moisturising substances is lessened by the thick

coating on hair, the occlusive effect of the sebum layer, and aid in moisture retention. Its absence has been linked to a number of skin problems, including psoriasis, dry skin, and atopic dermatitis [8].

Causes and mechanism of scalp scaling may be one of the following (Fig 1)

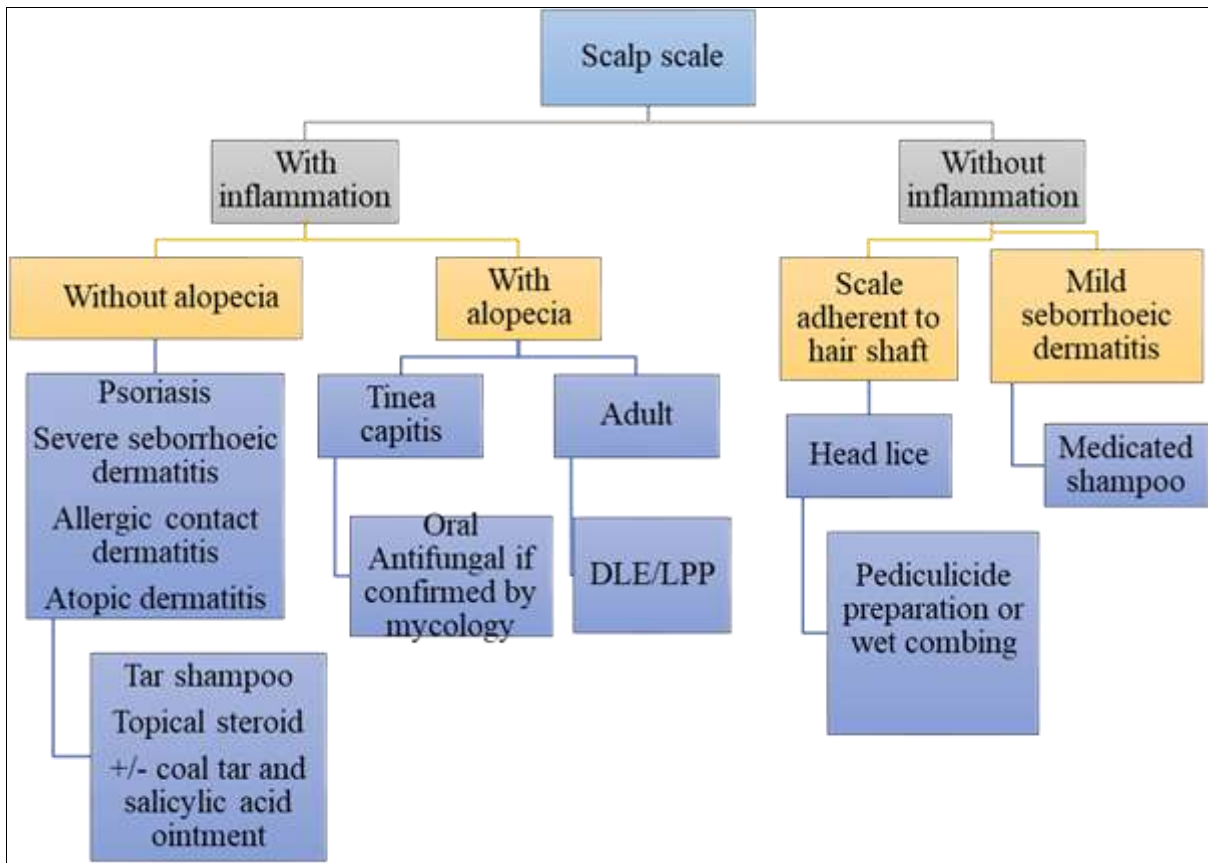


Fig 1: Recommendations for treating scaly scalp in basic care [2]

Physiologic scaling can occur through the continuous horny desquamation of stratum corneum because a new cell in the stratum basale needs two to four weeks to develop into a shed corneocyte.

A typical adult sheds 108 scales per day. The majority of these are made up of just one cell. When a person has dandruff, their rate of shedding is noticeably higher and a higher proportion of their scales contain many cells. Numerous scales have hundreds or even thousands of cells, and because of the accelerated SC turnover caused by this, the breakdown of filaggrin is not completely complete until modest levels of naturally occurring moisturising agents are produced. Hair keeps scale in place and enhances its visibility. For a week or two, simply skipping a few washes will result in the "appearance" of dandruff in the normal individual. On a scale, however, there are big disparities between severe dandruff and regular desquamation. On a scale, however, there are big disparities between severe

dandruff and regular desquamation. A person may shed up to 20 times as many scales as someone who is unaffected in the most severe cases of dandruff [7-9].

As a result, the stratum corneum of the flaking scalp exhibits significant characteristics that point to hyperproliferation, such as parakeratotic nuclear retention, atypical corneocyte structure, intracellular lipid droplets, and a lack of the orderly lamellar lipid structure [6].

Winter xerosis

Both internal (illness) and exterior (temperature, low humidity, and surfactants) factors might impair the scalp skin's barrier function (Figure 2). Winter xerosis may be made worse by seasonal variations in the quantities of the structural barrier lipids. One or more of these elements may increase the SC's susceptibility to disturbance, which could lead to dryness, agitation, and itching [6].

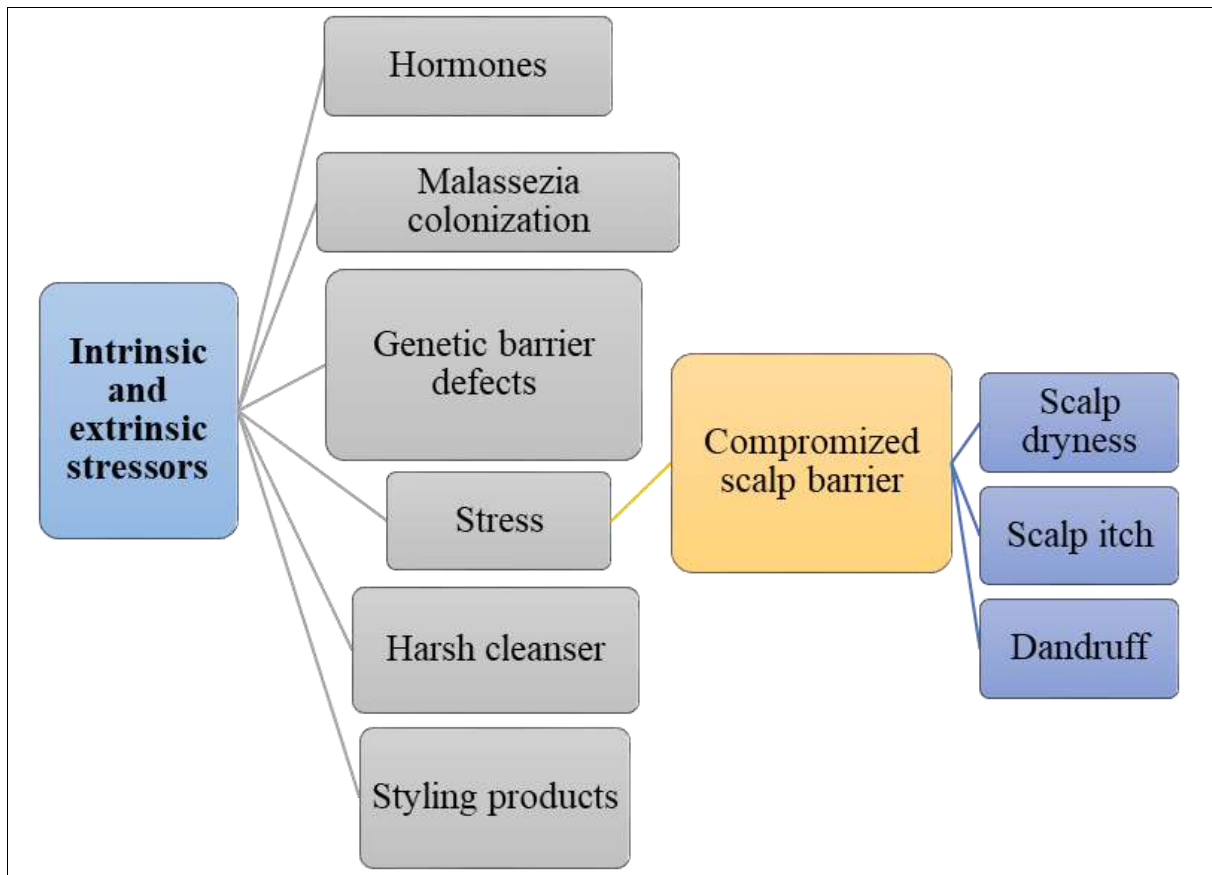


Fig 2: Dandruff barrier malfunction model ^[6]

Early studies on the dandruff-scalp SC discovered some similarities to the dry skin (xerosis) brought on by winter. Observations show that the dandruff scalp SC reflects a more serious breakdown of epidermal function, keratinization, and overall barrier integrity compared to normal dry skin found elsewhere on the body. Even while the loss of intercellular lipids in dry skin is less severe than that of dandruff, other symptoms of winter xerosis, such as parakeratosis, are rarely observed ^[6].

Variation in sebaceous gland activity ^[10] either by

- Malassezia, a lipophilic yeast that thrives in environments where sebum production is higher on the scalp, feeds on the lipids in sebum. As a result of changed sebum production, which also cause an increase in pro-inflammatory mediators like interleukin-8, the scalp becomes irritated, itchy, and flaky.
- Reduced sebum production has an effect on the stratum corneum's lipid layer, which may reduce the skin's ability to be protected by the lipid barrier. The lipid barrier becomes compromised, causing the scalp to dry out and produce flakes ^[11].

An immune-mediated aetiology that resembles psoriasis in which activated T cells enter the dermis and release cytokines that cause uncontrollable keratinocyte proliferation ^[12]. Psoriasis is also thought to develop from

seborrheic dermatitis as a result of a Koebner response to Malassezia yeast invasion. Similar clinical characteristics can be found in seborrhiasis, a condition that combines scalp psoriasis and seborrheic dermatitis ^[13].

1. Scales may or may not accompany alopecia

A common disorder in children that is commonly associated to tinea capitis ^[14].

2. Atopic dermatitis may be connected to scalp scaling

Studies of infants 0 to 6 months old and children from birth to 12 years old suggest that scaling of the scalp may be present in approximately half of all children with atopic dermatitis. Despite this, many doctors are unaware that scalp scaling is a symptom of atopic dermatitis because it is rarely included in most texts ^[5].

There are also huge, golden or silvery scales that enclose and bind hair tufts and seem like asbestos (Figure 3)

These typical scales have been called amiante or asbestos, as they are said to resemble white or grey fibrous minerals as in Pityriasis amiantacea (PA) which is typically considered to be a reactive condition to several inflammatory diseases, which may affect the scalp, mainly including psoriasis, atopic dermatitis and seborrheic dermatitis, lichen planus, lichen simplex chronicus, superficial fungal or pyogenic infection ^[15, 16].




Fig 3: Under a microscope, scale crusts that resemble amianth or asbestos can be seen sticking to multiple hair shafts in pityriasis amiantacea^[17]

So that a precise diagnosis may be made, a mucocutaneous examination can be carefully aimed to clarify the following:

- Typical psoriasis symptoms include Auspitz's sign, silvery-white scales, and oil-drop indications.
- Greasy-yellow scales of seborrheic dermatitis.
- Classic flexural involvement with severe itching and scratching of infantile atopic eczema
- Associated head lice infection of the scalp^[18].

Conflict of Interest

Not available

Financial Support

Not available

References

1. Hay RJ, Graham-Brown RA. Dandruff and seborrheic dermatitis: Causes and management. *Clin Exp Dermatol*. 1997;22(1):3-6.
2. Elston G, Davis R, Graham-Brown R. Dandruff and scaling scalp: management in general practice. *Prescriber*. 2006;17(11):13-7.
3. Grimalt R. A practical guide to scalp disorders. *J Invest Dermatol Symp Proc*. 2007;12(2):10-4.
4. Al-Refu K. The role of dermoscopy in assessment of the activity and scarring response in discoid lupus erythematosus. *The Open Dermatology Journal*. 2018, 12(1).
5. Williams JV, Eichenfield LF, Burke BL, Barnes-Eley M, Friedlander SF. Prevalence of scalp scaling in prepubertal children. *Pediatrics*. 2005;115(1):e1-e6.
6. Turner G, Hoptroff M, Harding C. Stratum corneum dysfunction in dandruff. *International journal of cosmetic science*. 2012;34(4):298-306.
7. Wilson M, Wilson PJ. Dandruff. In: Wilson M, Wilson PJ, editors. *Close Encounters of the Microbial Kind*. 1st ed. Switzerland: Springer; 2021 p. 83-98.
8. Bonnist E, Pudney P, Weddell L, Campbell J, Baines F, Paterson S, et al. Understanding the dandruff scalp before and after treatment: An *in vivo* Raman spectroscopic study. *International Journal of cosmetic science*. 2014;36(4):347-54.
9. Ackerman AB, Kligman AM. Some observations on dandruff. *J Soc Cosmet Chem*. 1969;20:81-101.
10. Ro BI, Dawson TL. The role of sebaceous gland activity and scalp microfloral metabolism in the etiology of seborrheic dermatitis and dandruff. *The journal of investigative dermatology Symposium proceedings*. 2005;10(3):194-7.
11. Yoon JS, Shim J, Lim JM, Park SG. Biophysical characteristics of dandruff-affected scalp categorized on the basis of sebum levels. *Journal of Cosmetic Dermatology*. 2021;20(3):1002-8.
12. Papp K, Berth-Jones J, Kragballe K, Wozel G, De La Brassinne M. Scalp psoriasis: A review of current topical treatment options. *Journal of the European Academy of Dermatology and Venereology*. 2007;21(9):1151-60.
13. Phiske MM. Scalp Psoriasis: A Brief Overview. *J Cosmo Trichol*. 2016;2(2).
14. Betilloch-Mas I, Albares-Tendero M, Soro-Martínez M, Pérez-Crespo M. Persistent desquamation of the scalp as a manifestation of tinea capitis in Sub-Saharan children. *Journal of immigrant and minority health*. 2015;17(5):1588-90.
15. Errichetti E, Stinco G. Dermoscopy as a useful supportive tool for the diagnosis of pityriasis amiantacea-like tinea capitis. *Dermatology Practical & Conceptual*. 2016;6(3):63.
16. Abdel-Hamid IA, Agha SA, Moustafa YM, El-Labban AM. Pityriasis amiantacea: a clinical and etiopathologic study of 85 patients. *International journal of dermatology*. 2003;42(4):260-4.
17. Verardino GC, Azulay-Abulafia L, Macedo PMd, Jeunon T. Pityriase amiantácea: aspectos clínicos e dermatoscópicos e microscopia dos tufos capilares. *Anais Brasileiros de Dermatologia*. 2012;87:142-5.
18. Kansal NK, Agarwal S. An itchy, scaly plaque on the scalp. *Australian Family Physician*. 2015;44(8):571-2.

How to Cite This Article

Yousef SA, El-Attar YA, El-Guindy DM, Nabil N. Mechanisms and causes of Scalp Scaling. *International Journal of Dermatology, Venereology and Leprosy Sciences*. 2023; 6(1): 122-125.

Creative Commons (CC) License

This is an open access journal, and articles are distributed under the terms of the Creative Commons Attribution-Non Commercial-Share Alike 4.0 International (CC BY-NC-SA 4.0) License, which allows others to remix, tweak, and build upon the work non-commercially, as long as appropriate credit is given and the new creations are licensed under the identical terms.